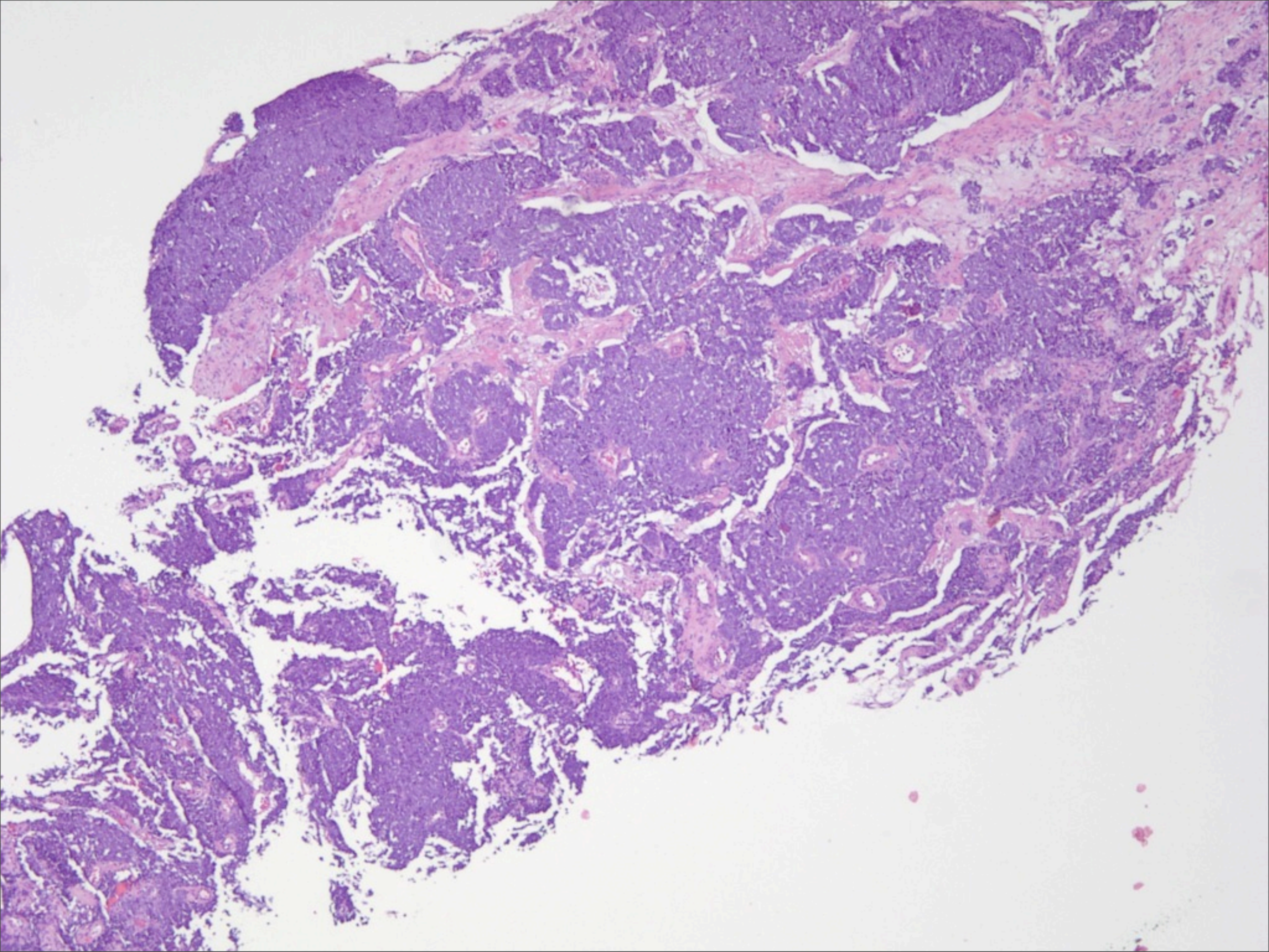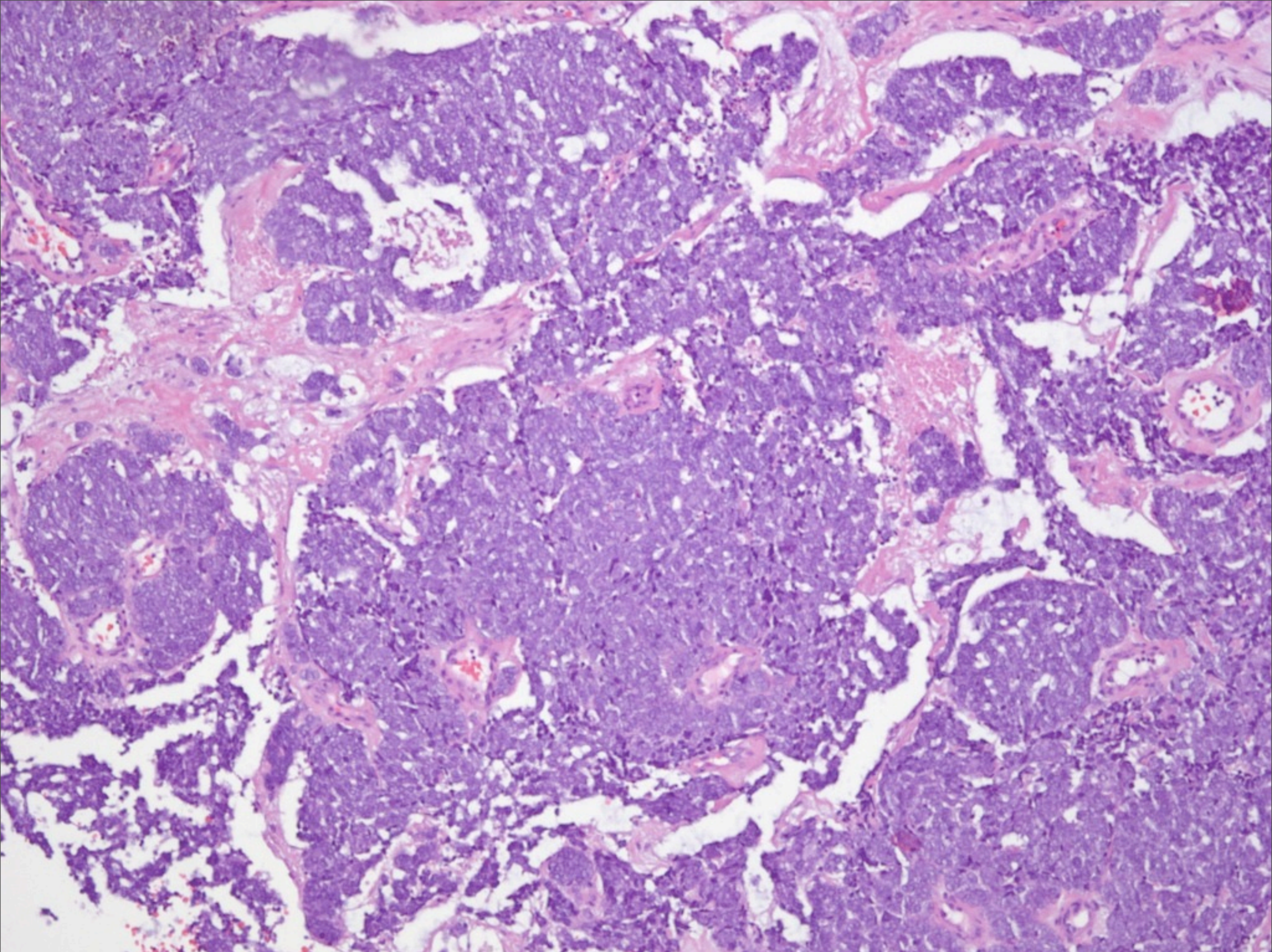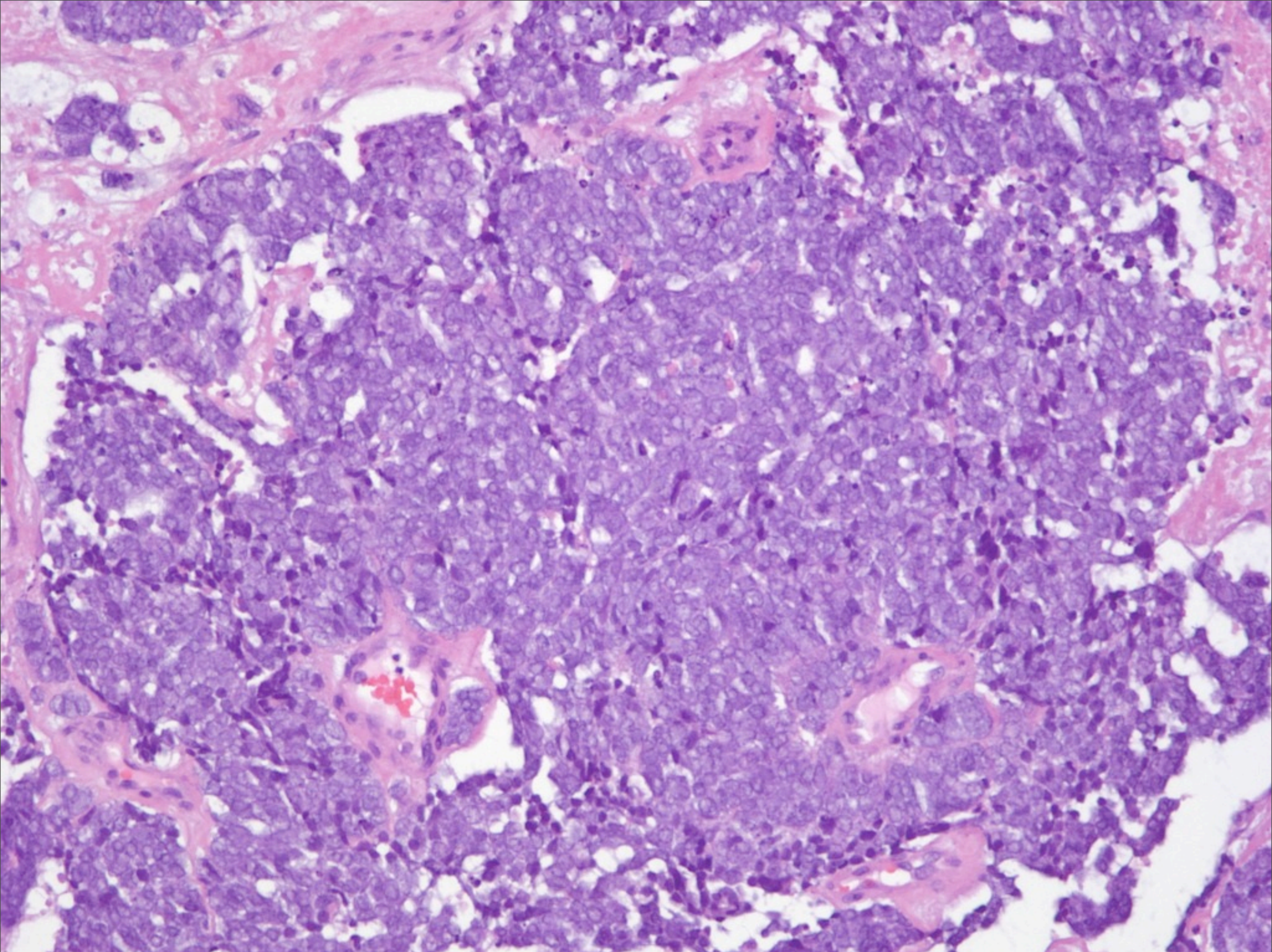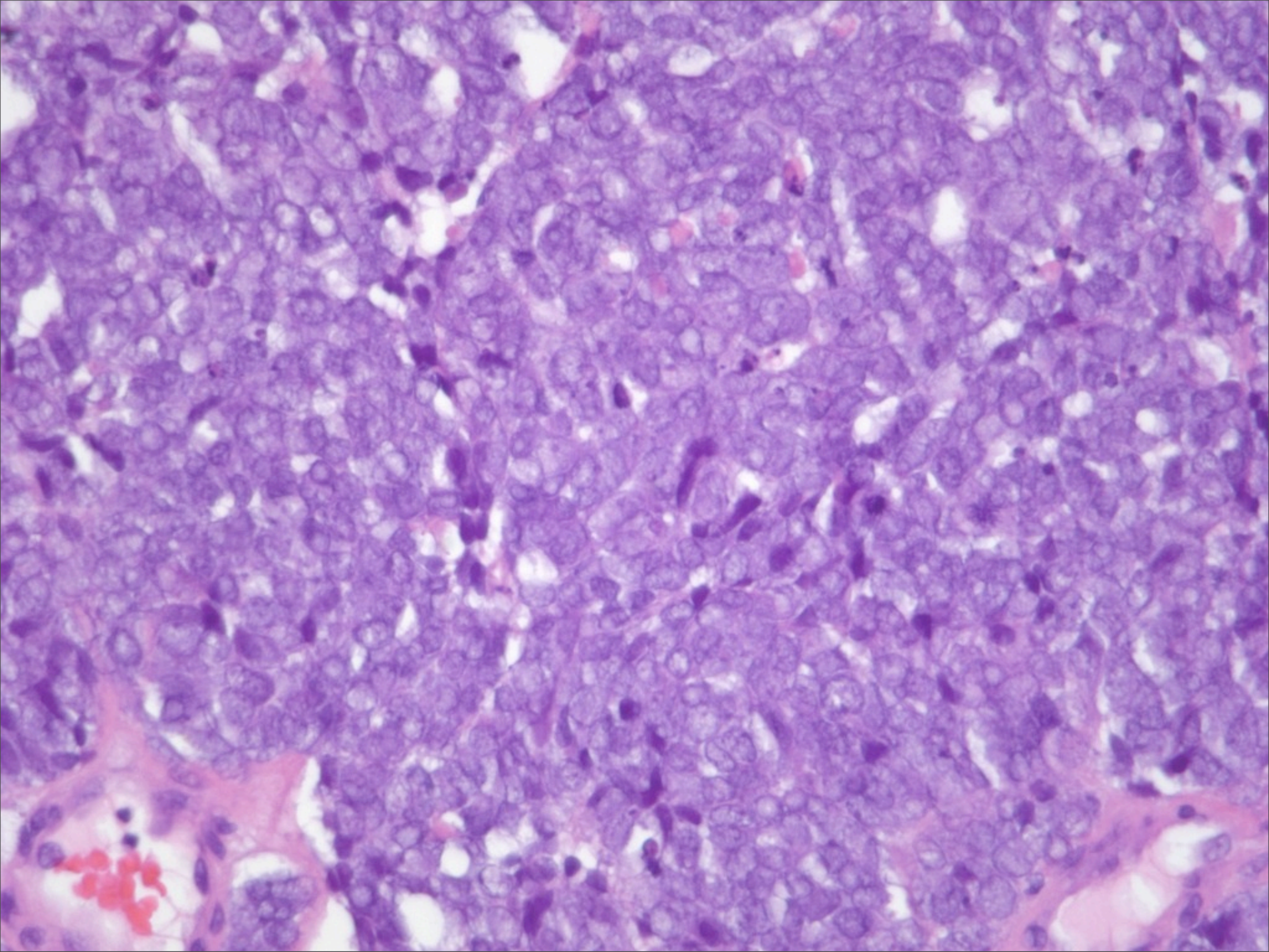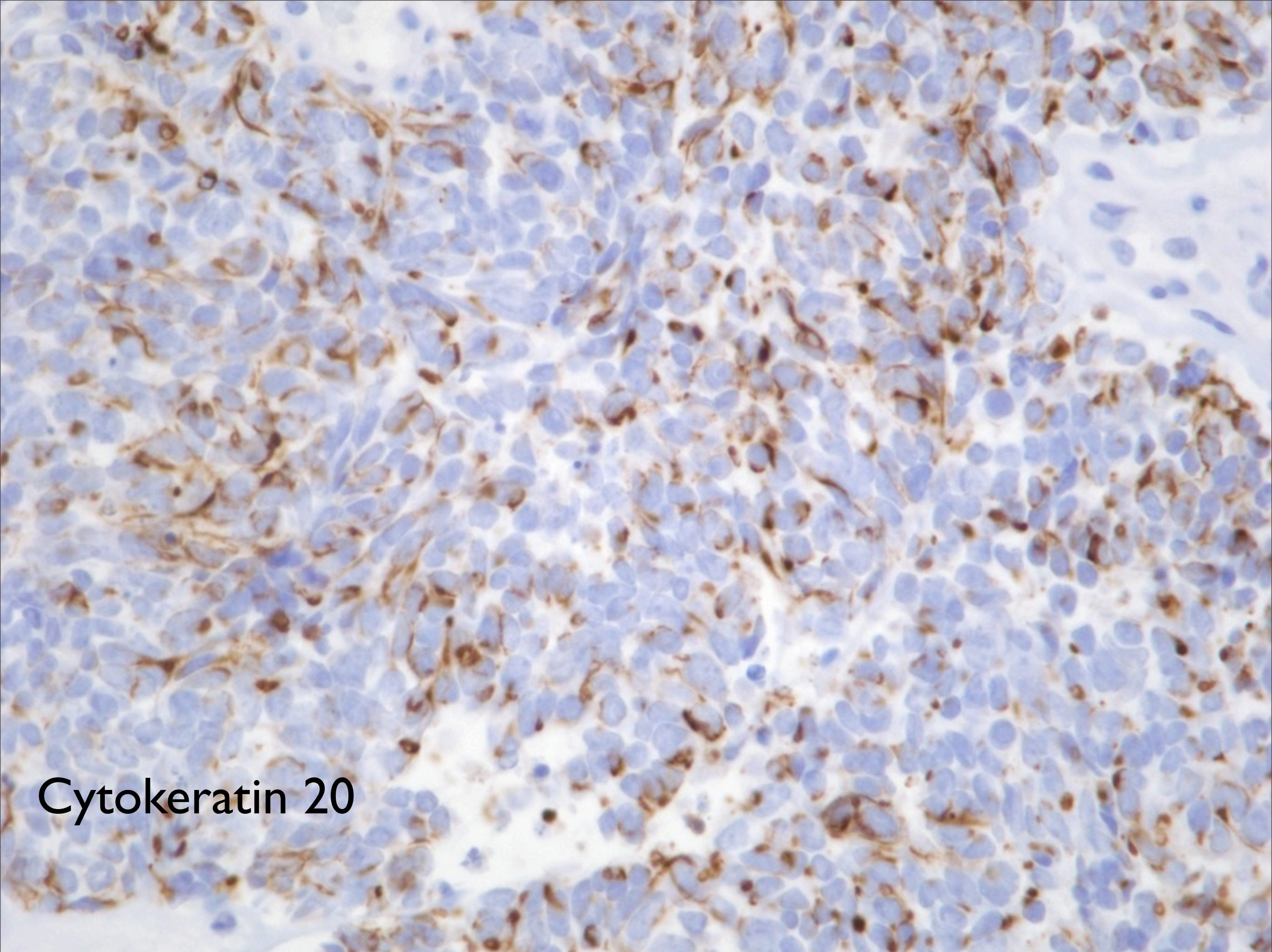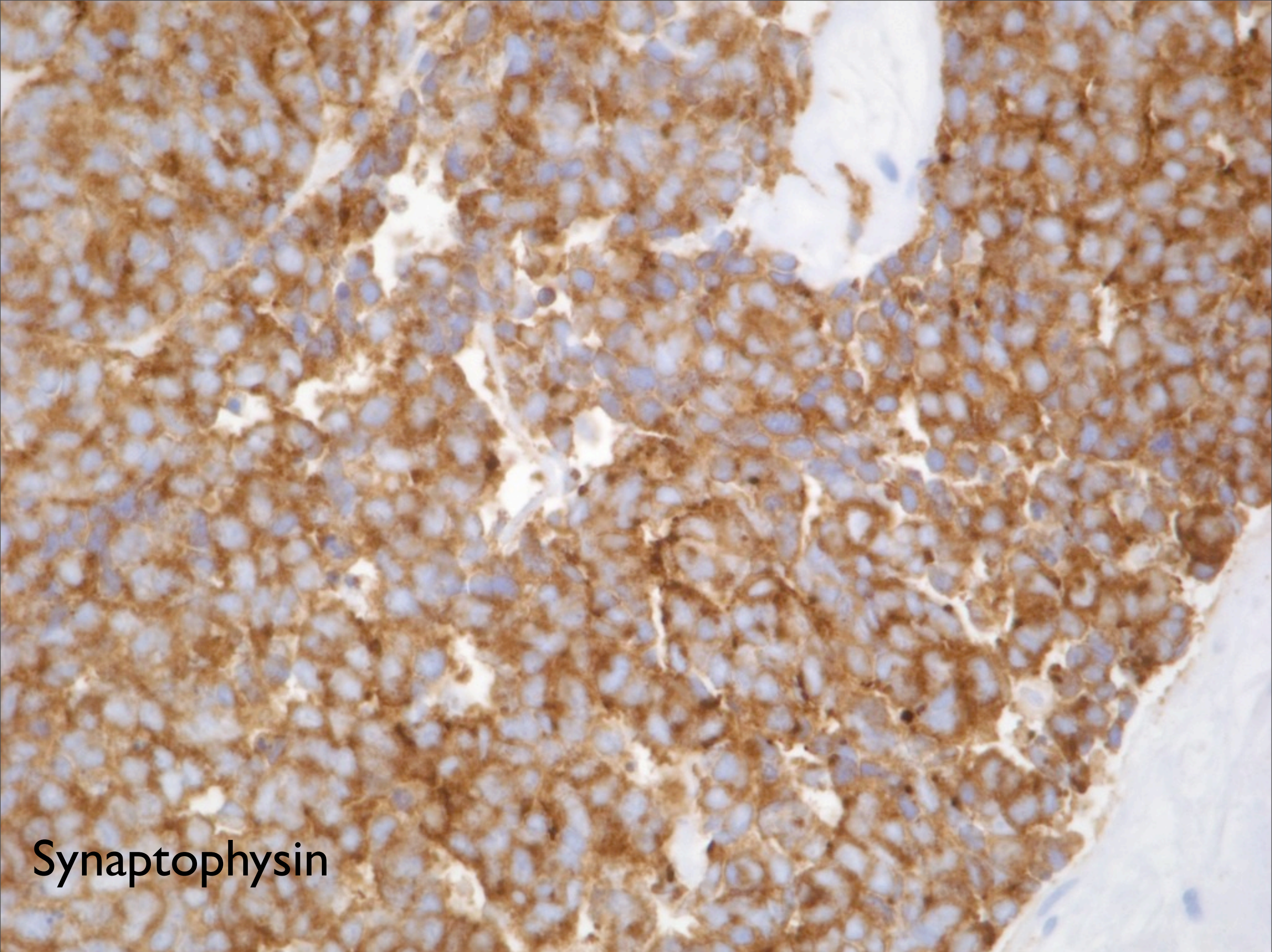


Cytokeratin 20





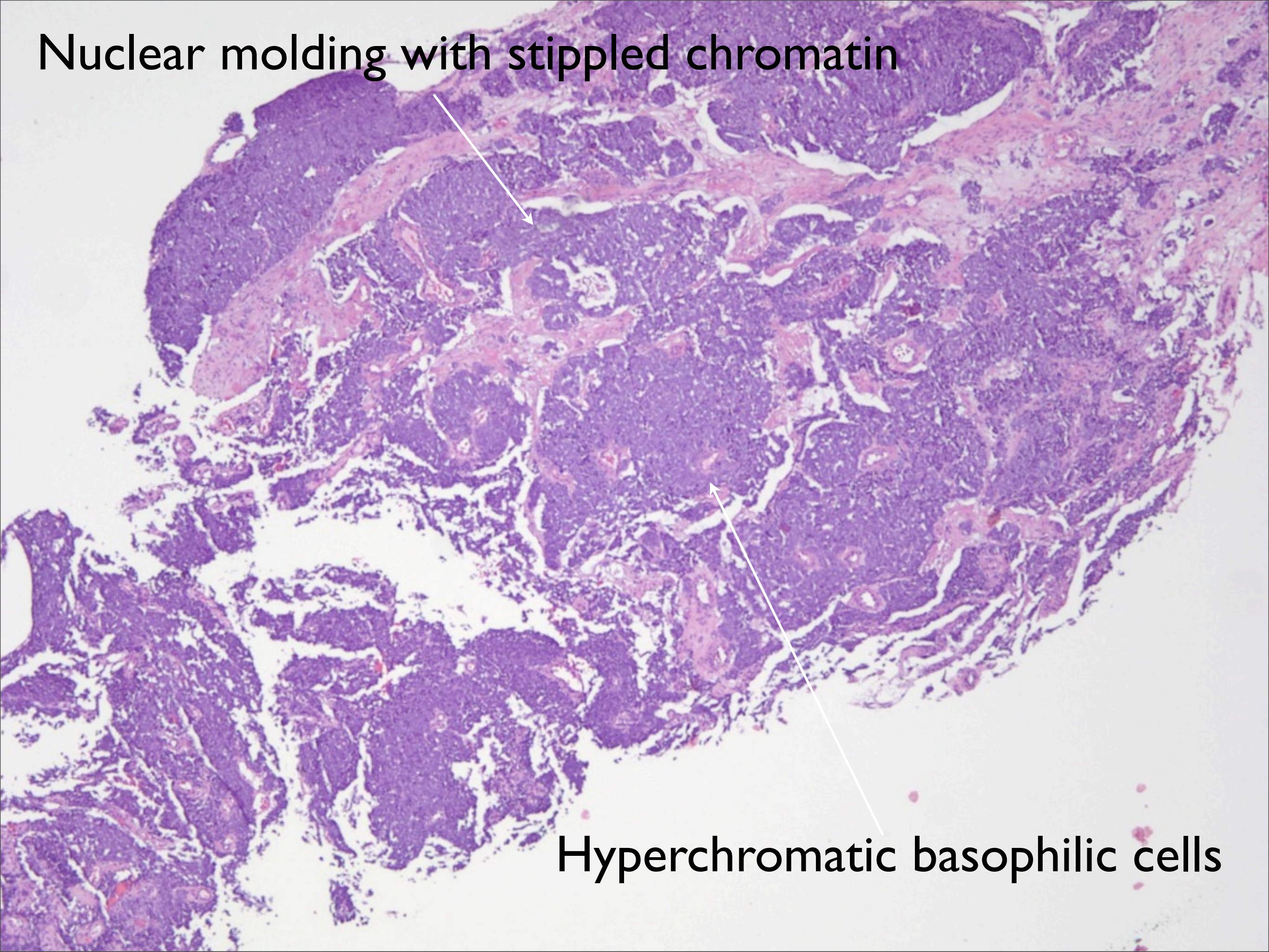
Synaptophysin



# Merkel Cell Carcinoma

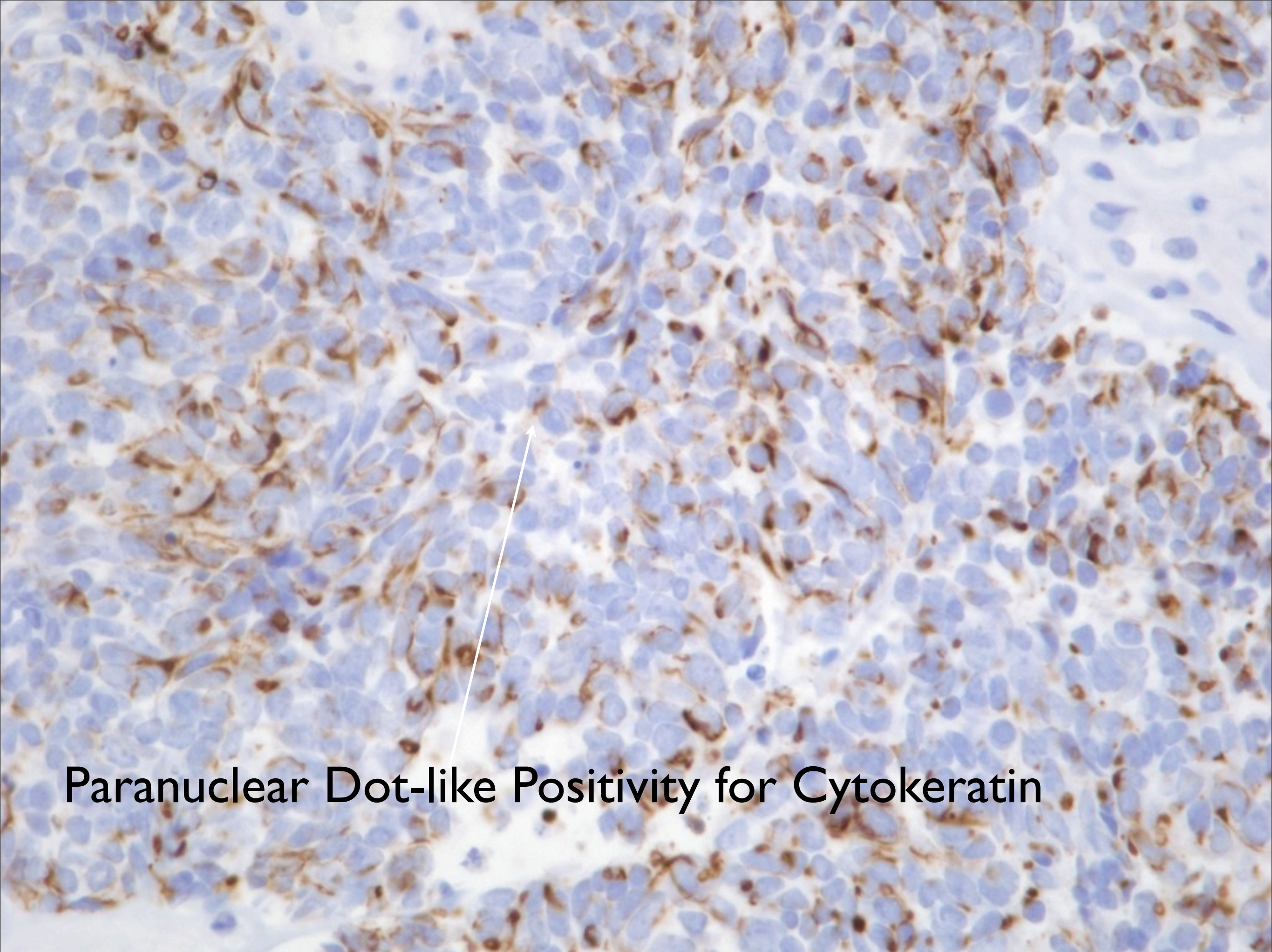


Nuclear molding with stippled chromatin



Hyperchromatic basophilic cells





Paranuclear Dot-like Positivity for Cytokeratin